

A STUDY ON DIVISION OF BRACHIAL ARTERY AND ITS CLINICAL CORRELATIONS

Subhash M. Gujar ^{*1}, Sunil G. Oza ², Jaidevsingh P. Shekhawat ³, Sanjay K. Vikani ⁴, Sweta B. Prajapati ⁵.

^{*1, 2, 3} Assistant Professor, Department of Anatomy, ⁵ Assistant Professor, Department of Microbiology, C.U.Shah Medical College, Surendranagar. India. ⁶ Assistant Professor, Department of Anatomy, GMERS Medical College, Patan, India.

ABSTRACT

Background: The brachial artery begins as the continuation of 3rd part of axillary artery at the distal border of teres major muscle. It terminates about a centimetre below the elbow joint at the level of neck of radius into radial and ulnar arteries.

Context & purpose of study: The present study was done on 30 cadavers in department of anatomy to find out any variations in division pattern of the brachial artery.

Results: Variations were found in two cadavers. An unusual short segment of the brachial artery which divide at middle of arm was found in right upper limb of one cadaver. There was a high origin of the radial artery from axillary artery found in right upper limb of one cadaver. The variations can be explained on the basis of embryological development.

conclusions: The knowledge of branching pattern of brachial artery is useful for physicians, surgeons, nephrologists, radiologist and interventionist in various surgical procedures and also for diagnostic and therapeutic approaches.

KEYWORDS: Brachial artery; Radial artery; Ulnar artery; Variations.

Address for Correspondence: Dr. Subhash M. Gujar, Assistant Professor, Department of Anatomy, C.U.Shah Medical College, Surendranagar, India. **E-Mail:** subh_26284@yahoo.co.in

Access this Article online

Quick Response code



Web site: International Journal of Anatomy and Research
ISSN 2321-4287
www.ijmhr.org/ijar.htm

Received: 12 Jan 2014

Peer Review: 12 Jan 2014 Published (O):30 March 2014

Accepted: 12 Feb 2014 Published (P):30 March 2014

BACKGROUND

The brachial artery is a continuation of the axillary artery. It begins at lower border of teres major muscle and terminates by dividing into the radial and the ulnar arteries at a point about finger's breadth below the bend of elbow. As the brachial artery runs along a line from the medial lip bicipital groove behind the coracobrachialis muscle to the middle of the cubital fossa at a point level with the neck of the radius. The median nerve is closely related to the brachial artery. It lies lateral to the brachial artery in the upper part of arm and crossing the artery in front and lies medial to it in lower part of the arm. The brachial artery gives profunda brachii artery, superior ulna collateral artery, inferior ul-

nar collateral artery, muscular branches and two terminal branches [1].

An intimate knowledge of arterial anatomy of upper extremities and its common variations is indispensable to limb surgeons. Appreciation of variations in the upper extremity vasculature is essential to prevent injury, thrombosis, gangrene and even amputation of limbs, particularly in patients requiring dialysis or undergoing arteriography. For both surgical and routine patient can accurate knowledge of course and relations to surrounding structures is of great Importance [2].

The variations of the arterial system of the upper limb have been well documented by many the

variations of the arterial system of the upper limb have been well documented by many authors and have a considerable significance towards the clinical and surgical point of view. The major variations in the arterial patterns reported are the higher origin of radial and ulnar arteries.

Arey(1957) is of the view that the anomalous blood vessels may be due to (i) the choice of unusual paths in the primitive vascular plexuses, (ii) the persistence of vessels normally obliterated, (iii) the disappearance of vessels normally retained, (iv) incomplete development and (v) fusions and absorption of the parts usually distinct [3].

Anatomical variations of this artery occur in almost 20% of the cases and are commonly found in routine dissections or clinical practice [4]. The brachial artery may be absent in rare cases (5); divided in a higher level [6], trifurcating [7] and originating accessory branches that may or may not bifurcate into radial and ulnar arteries (5, 8).

According to Compendium of Human Anatomic variation, major variations are present in about 25% of the subjects studied for the brachial artery. The variations in the form of high proximal division into terminal branches occur in the radial artery (15%), ulnar artery (2%) and common interosseous artery. This high division may occur at any point in the normal course of the vessel, but it is more common in the middle third. The two vessels run parallel to each other to the bend of the elbow, in the usual position of the brachial artery. From this point, one branch follows the normal course of the radial artery through the forearm and the other one takes the normal course of the ulnar artery. This arrangement is considered a simple high division of the brachial artery [9].

MATERIALS AND METHODS

The present study was done on 30 cadavers in the department of anatomy. The specimens were dissected by using scalpel and forceps. An incision was made in the upper limb from axilla to wrist. The skin & fascia were exposed in layers. The axillary artery & brachial artery were traced carefully for any variations.

RESULTS

Among the 30 cadavers, variations were found in two cadavers. In one cadaver (Fig-1), the brachial artery was divided in middle third of arm into radial and ulnar arteries. The profunda brachii arose from brachial artery before its division. The superior and inferior ulnar collateral branches arose from the ulnar artery. The radial artery and ulnar artery passed downward along lateral and medial border of biceps brachii respectively. The remaining course of both arteries were normal. In one cadaver (Fig-2), the radial artery arose from 3rd part of axillary artery from ventral side in axilla. The radial artery passed downward & cross median nerve from medial to lateral side & then pass along medial side of the biceps brachii muscle. In lower part of arm it cross tendon of biceps brachii. So in cubital fossa structure were Median nerve, Ulnar artery, Biceps tendon, radial artery & Radial nerve from medial to lateral side. During its way radial artery sent off a lot of muscular branches & some cutaneous branches. The profunda brachii, superior & inferior ulnar collateral branches were arose from ulnar artery.

DISCUSSION

Anomalies of the forelimb arterial tree fairly common. This is mainly because of their multiple and plexiform sources, the temporal succession of emergence of principal arteries, anatomises and periarticular networks and functional dominance followed by regression of some paths.

Occasionally the artery divides proximally into two trunks, which may reunite. Frequently it divides more proximally than usual, and this unusually short segment brachial artery may bifurcate as usual or it may trifurcate into radial, ulnar and common interosseous arteries. More often the radial branches arise proximally, leaving a common trunk for the ulnar and common interosseous; sometimes the ulnar artery arise proximally, the radial and common interosseous forming the other division; the common interosseous may also arise proximally [1].

In our study early bifurcation of brachial artery was found in middle of the arm in 1 cadaver out of 30 cadavers. High bifurcation of the brachial artery was found in only 0.5% in 202 cadavers

dissected by Bertolazzo, Romero, Bica et al.(1981) [10].In a study involving 72 upper limbs Brazilian adult cadavers of both sexes, the bifurcation of the brachial artery was found above bicondylar line in 11.1% cases [11]. Namani Satyanarayana et al.(2010) also documented a case of early division of brachial artery in middle of right arm into radial and ulnar artery both of same calliper [12]. High division of brachial artery in the proximal third of arm was found in 3 cases out of 60 specimens by Vandana R. , N.M.suresh et al. (2012) [13]. An unusually short segment brachial artery with bifurcation proximal at the level of insertion of coracobrachialis was noted in 2 out of 20 cadavers by Jitendra Gupta et al. (2012) [14]. Higher division of brachial artery with superficial course of radial artery was found in 3 cases out of 48 cadavers in study by Dr. Padma Varlekar et al. (2013)[15].

High origin of the radial artery from 3rd part axillary artery was found in 1 case out of 30 cadavers in our study.

Table 1: Comparison of origin of radial artery from axillary artery in different studies.

Authors	Year	Percentage %
Keller et al.	1980	2.13%
Uglietta et al.	1989	2%
Baeza A et al.	1995	0.66%
Niefenfuhr et al.	2001	10.40%
Konarik et al.	2009	3%
Vandana et al	2012	8.30%
Chandni Gupta et al.	2012	2.66%
Present study	2013	3.33%

Table1: shows origin of Radial artery from axillary artery in different studies. Gonzalez- compta reported vascular variations of the hand in association with radial artery arising from axillary artery [20].

Icten et al found radial artery arising from the axillary artery bilaterally in a cadaver [21]. Okaro and jiburum had reported an incidence of radial artery arising from the axillary artery bilaterally in an adult Nigerian cadaver[22]. Balchandra et al reported a case of high origin of radial artery from 3rd part of axillary artery proximal to the two roots of the median nerve [23]. The unusual division of brachial artery can be explained on the basis of embryological development of vessels of upper limb.

Singer [24] staging of development:

Stage1: The lateral branch of seventh intersegmental artery, i.e., subclavian artery extends to the wrist and terminates by forming capillary plexus; its distal portion forms the anterior interosseous artery.

Stage 2: Median artery arises from the anterior interosseous artery grows along the median nerve to communicate with palmar capillary plexus. By this time the anterior interosseous artery undergoes regression.

Stage 3: The ulnar artery arises from brachial artery and unites distally with the existing median artery to form superficial palmar arch.

Stage 4: The superficial brachial artery develops in axillary region from the axial trunk and traverses the medial surface of the arm, runs diagonally from the ulnar to the radial side of the forearm to the posterior surface of the wrist to divide over the carpus into digital branches.

Stage 5: Three changes occur simultaneously The median artery regresses to a small slender vessel, familiar in adult life as the arteria nervi mediana.

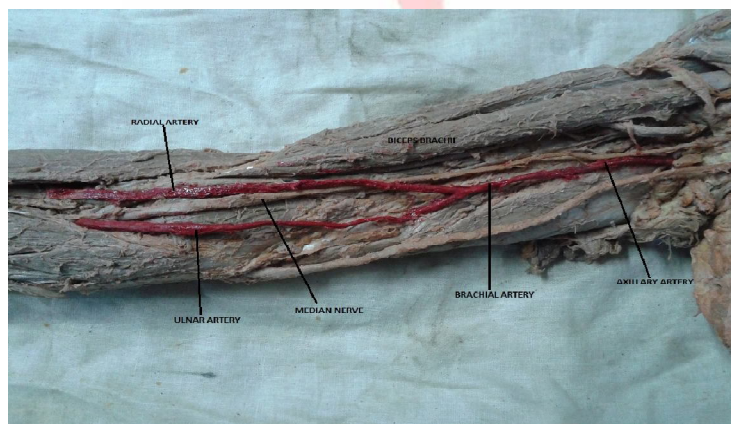


Fig. 1: Higher division of Brachial artery in Middle third of Arm.

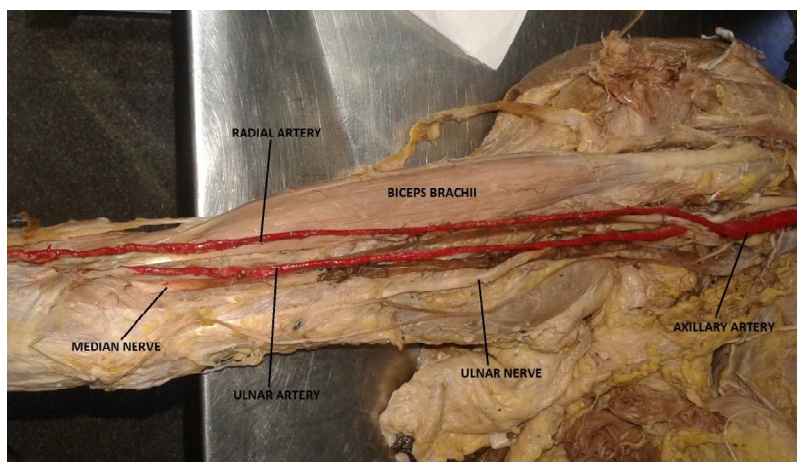


Fig. 2: High origin of radial artery from 3rd part of axillary artery.

The superficial brachial artery gives off a distal branch which anastomoses with the superficial palmar arch formed already.

At the elbow, an anastomotic branch develops between the main trunk of brachial artery and the existent superficial brachial artery. The distal part of superficial brachial artery enlarges to form the radial artery whereas the proximal portion of superficial brachial artery atrophies correspondingly.

In the present study, the superficial brachial artery, instead of regression was retained as high origin of radial artery.

CONCLUSION

The vessels of the upper limb have much more importance in different kinds of diagnostic, analytical and therapeutic studies. In congenital, inflammatory, metabolic and regenerative diseases, the study of basic anatomy is important for understanding circulation of the blood flow to improve the operative outcome. In orthopaedic surgeries around elbow, accidental crush injuries leading to haemorrhage requires its special mention.

Superficial radial artery can be mistaken for a vein and accidental injection of certain drugs in this artery may cause reflex vascular occlusion resulting in disastrous gangrene of hand. Variations in the arterial tree may be encountered during arteriographic examination, percutaneous brachial catheterisation and skin flap elevations from the arm or forearm.

Computer highlighted diagnostic, interventional and surgical significance of such a variation. Diagnostically this type of variation may disturb the evaluation of angiographic images. Further

knowledge of such variation has got clinical importance especially in field of orthopaedic, plastic and vascular surgeries [20].

Conflicts of Interests: None

REFERENCES

- [1]. Williams, Bannister, Berry MM, Collins P, Dussek JE, Ferguson MW, eds. Gray's Anatomy 38th edition, London, Churchill Livingstone. 1999; 319,1539.
- [2]. Chandni Gupta, Vikram Palimar, Murlimanju BV, Vaishali R Shetti. A morphological study of variations in the origin and course of radial artery. Research Journal of Pharmaceutical, Biological and Chemical Sciences April-June 2012;3(2):333.
- [3]. Arey, L.B. : Developmental Anatomy In: Development of the Arteries, 6th Edn, W.B. Saunders' co; Philadelphia, pp. 375-77 (1957).
- [4]. Lippert, h. and pabst, R. Arterial variations in man. Munich: Bergman, 1985. p. 66-77.
- [5]. McCormack, L.J., caulwell, EW. and anson, bj. Braquial and antebrachial arterial patterns. Surgery, Gynecology & Obstetrics 1953;96:43-54. PMID:13015348.
- [6]. Ciervo, a., kahn, m., pangilinan, aj. And dardik, h. Absence of the braquial artery: Report of a rare human variation and review of upper extremity arterial anomalies. Journal of Vascular Surgery 2001;33:191-4. PMID:11137944.
- [7]. Malcic-gurbuz, j., gurunluoglu, r., ozdogmus, o. And yalin, a. Unique case of trifurcation of the brachial artery: Its clinical significance. Clinical Anatomy. 2002;15:224-7.
- [8]. Yang, hj., gil, yc., jung, ws. And lee, hy. Variations of the superficial brachial artery in Korean Cadavers. Journal of Korean Medical Science 2008;23:884-7.
- [9]. Bergman RA, Thompson SA, Afifi AK, Saadeh FA. Compendium of human anatomic variation. Baltimore: Urban & Schwarzenberg; 1988.
- [10]. Bertolazzo, w., romero, am., bica, dt., cavaleiro,fc., barroso filho, f., pezzi, lh. And kauffman, l. Variação anatômica da artéria braquial bifurcação alta. Revista Brasileira de Cirurgia 1981;71(3):173-80.
- [11]. Olave, e., braga, mtt., gabrielli, c. And rodrigues, cfs. Nivel de bifurcacion de la arteria braquial y sus

- relaciones con el nervio mediano. Revista Chilena de Anatomía, 1997;15:1.
- [12]. Namani Satyanarayana et al. Brachial artery with high up division with its embryological basis and clinical significance. Int J Anatomical variations (2010)3:58.
- [13]. Vandana R et al , Variation in course and branching pattern of Brachial artery. Anatomica Karnataka 2012;6(3):42-48.
- [14]. Jitendra Gupta et al. A study of brachial artery with high up division and its clinical significance. Int J Bioassays 2012;01(11):116-118.
- [15]. Padma Varlekar et al. Higher bifurcation of brachial artery with superficial course of radial artery in forearm; Int J of Med Sci Public Health 2013;2:703-706.
- [16]. Keller F S, Rosch J, Dotter C T and Porter J M. Proximal origin of radial artery; Potential pitfall in hand anigography. American Journal of Roentgenology 1980;134(1)169-70.
- [17]. Uglietta JP, Kadir S. Cardiovascular and Interventional Radiology 1989;12:145-148.
- [18]. Rodriguez NM, Vazquez T, Nearn L, Ferreira B, Parken I, Sanudo JR. J Anatomy 2001;199(5):547-566.
- [19]. Konarik M. Superficial brachioradial artery : a case report and its embryological background. Folia Morphol.2009;68:174-178.
- [20]. Gonzalez-Compta X. Origin of the radial artery from the axillary artery and associated hand vascular anomalies. J Hand Surg Am. 1991;16:293–296.
- [21]. Icten N, Sullu Y, Tuncer I. Variant high-origin radial artery: a bilateral case. Surg Radiol Anat. 1996;18:63–66.
- [22]. Okoro IO, Jiburum BC. Rare high origin of the radial artery: a bilateral, symmetrical case. Nig J Surg Res. 2003;5:70–72.
- [23]. Balchandra N et al; Unusual origin of the radial artery, Int j of Anatomical variations 2011;4:101-103.
- [24]. Singer E. Embryological patterns persisting in the arteries of the arm. Anatomical Record 1933;55:406-413.

How to cite this article:

Subhash M. Gujar, Sunil G. Oza, Jaidevsingh P. Shekhawat, Sanjay K. Vikani, Sweta B. Prajapati. A STUDY ON DIVISION OF BRACHIAL ARTERY AND ITS CLINICAL CORRELATIONS. Int J Anat Res 2014;2(1):208-12.